

Neonatal Lupus Erythematosus: Clinical Findings and Pathogenesis

Lela A. Lee

University of Colorado School of Medicine, Denver Health Medical Center, Denver, Colorado, USA

Neonatal lupus erythematosus is an uncommon disease associated with maternal autoantibodies to proteins of the Ro/La (SSA/SSB) family. The clinical findings most often reported are third-degree heart block and cutaneous lupus lesions, but a significant number of children have cardiomyopathy, hepatobiliary disease, or hematologic cytopenias. The consistent presence of maternal autoantibodies and the transient nature of the disease implicate maternal autoantibodies as the cause

of the disease, and developing animal models support the concept that the autoantibodies are pathogenic. Only a minority of babies exposed to the autoantibodies develop disease, however, and mothers and their babies have different disease manifestations. Thus, additional factors are likely to be important in determining disease expression. Key words: autoantibody/heart block/Ro/La. J Invest Dermatol Symp Proc 9:52–56, 2004

Half a century ago, McCuiston and Schoch described a case of transient lupus skin lesions occurring in a baby whose mother was ANA positive (McCuiston and Schoch, 1954). This was the first report of neonatal lupus (NLE). Although NLE is an uncommon disease, several hundred cases have been reported. It is now known that NLE occurs in the offspring of mothers who have anti-Ro (SSA) autoantibodies and that it may manifest as skin, cardiac, hepatobiliary, or hematologic disease. This review will focus on recent advances in the understanding of the clinical features of NLE and its pathogenesis.

CLINICAL FINDINGS

Cutaneous NLE Cutaneous NLE lesions typically appear a few days to weeks after birth, but they have been noted at birth in some cases (Lee, 1999). Lesions are most likely to occur on the face and scalp, but may also occur on the extremities and trunk, including the diaper area. The morphology is characteristically that of an annular erythema with central clearing and raised red borders (Fig 1), but lesions may sometimes have fine scale or crusting. Histology of the lesions is identical to that of subacute cutaneous lupus of adults, with keratinocyte damage and a superficial mononuclear cell infiltrate, but little or no follicular plugging or scarring. Resolution of active disease takes place within weeks or months, although dyspigmentation may persist for many months or years and permanent telangiectasia may occur.

A review of 18 cases of NLE evaluated at the University of Colorado noted a predominance of females (14 females, 4 males) and a frequent occurrence of periorbital lesions that impart an "owl eye" or "eye mask" appearance (Weston *et al*, 1999). Photosensitivity was observed in 12 cases, and features of cutis

marmorata telangiectasia congenita were observed in 4. Residual telangiectasias were present in 4 children. Remarkably, in 17 of 18 cases the diagnosis of NLE was not suspected until the dermatology consultation.

It is common in NLE for there to be only one organ noted to be affected, and indeed the skin was apparently the only organ affected in 12 of 18 cases. In 2 cases, there was skin disease and heart block; in 3 cases, skin lesions, hepatobiliary disease, and thrombocytopenia; and in 1 case, skin disease, heart block, and thrombocytopenia. Although heart block is the finding of NLE most emphasized, it appears that children who have NLE skin lesions may be as likely to have hepatobiliary or hematologic disease as heart disease.

The Research Registry for Neonatal Lupus, established in 1994, is a repository of cases from the United States and is likely the largest collection of cases in the world. The clinical characteristics of 57 cases of cutaneous NLE in the absence of heart block were reported from the registry database. These findings confirm female predominance (37 females, 20 males), frequent involvement of the skin of the face and scalp (especially the periocular skin), frequent photosensitivity, and occasional residual telangiectasia or dyspigmentation (Neiman *et al*, 2000).

Cardiac NLE The cardiac disease of NLE is characteristically congenital complete (third-degree) heart block (CHB) (Lee, 1999). CHB almost always begins *in utero* during the second or third trimester. Occasionally, a lesser degree of block that may progress to third degree is initially noted. Autopsy studies have shown a replacement of the atrioventricular nodal area by fibrosis and calcification. If this finding is also representative of the cardiac pathology in children who survive, replacement of nodal tissue by fibrosis explains why CHB is almost always permanent.

Perhaps surprisingly, some children with CHB are able to compensate for the slow heart rate and do not require therapy. Many require pacemaker implantation, however. In some cases, cardiomyopathy occurs in addition to the conduction system abnormality. In children with significant cardiac muscle involvement, correction of the heart rate with a pacemaker may not

Manuscript received September 16, 2002; revised November 10, 2002; accepted for publication January 13, 2003

Correspondence and reprint requests to: Lela A. Lee, Denver Health Medical Center, Mail Code 4000, 777 Bannock St., Denver, CO 80204, USA. Email: lela.lee@uchsc.edu

Abbreviations: ANA, antinuclear antibodies; CHB, congenital heart block; NLE, neonatal lupus erythematosus.

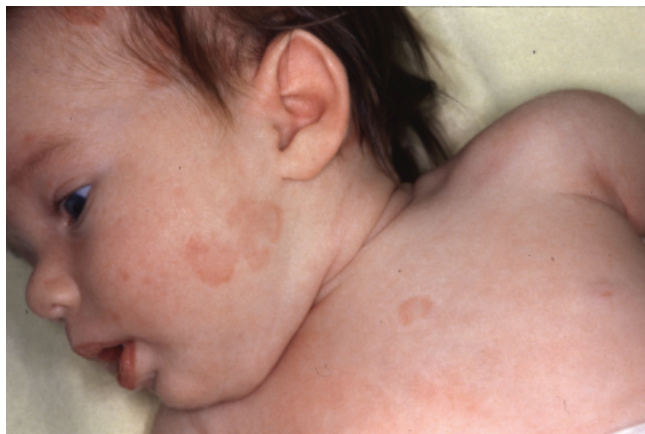

Figure 1. Characteristic annular erythematous lesions on the face of a child with cutaneous neonatal lupus.

suffice to correct heart failure and the outcome is often fatal. Most cases of significant cardiac muscle involvement are evident at birth or shortly thereafter, but cases of cardiomyopathy have developed a few months after birth, indicating the need for continued close monitoring of children who have cardiac NLE (Taylor-Albert *et al*, 1997).

The registry reported information from 113 cases of cardiac NLE (Buyon *et al*, 1998). There were approximately equal numbers of males and females. Heart block was usually detected in the second or early third trimester, with a median gestational age at detection of 23 weeks. In this database, 63% of children required pacemakers and about 20% died as a result of cardiac failure.

Hepatobiliary disease Almost all cases of hepatobiliary disease associated with NLE have been in children who had cardiac or cutaneous lesions, although there have been case reports of hepatobiliary disease occurring as an isolated finding (Schoenlebe *et al*, 1993; Selander *et al*, 1998). In a review of data from the registry, the following types of hepatobiliary involvement were found: (1) liver failure occurring *in utero* or shortly after birth and often having the clinical phenotype of neonatal iron storage disease or neonatal "hemochromatosis"; (2) transient conjugated hyperbilirubinemia occurring in the first few weeks of life; and (3) transient elevations of aminotransferases occurring at about two or three months of age (Lee *et al*, 2002). Evidence of hepatobiliary involvement was present in about 10% of cases in the registry. It is quite possible that the percentage of cases affected is actually higher, as most cases had no documentation of liver enzymes having been checked.

Hematologic disease Thrombocytopenia has been noted in several cases of NLE (Watson *et al*, 1988) and may occur in as many as 10% of cases of cardiac or cutaneous NLE. It is transient and often clinically benign, but there has been at least one case of gastrointestinal bleeding attributed to it (Lee, 1999).

Neutropenia has been reported in NLE only infrequently, but, it occurred in 5 of the 57 children with cutaneous NLE entered in the registry (Neiman *et al*, 2000; Kanagasegar *et al*, 2002). Lymphopenia, which has been reported to have some correlation with anti-Ro autoantibodies in adults, has not been a feature of NLE. Anemia, which has in some cases been characterized as hemolytic anemia, has been reported occasionally.

THERAPY

The management of cutaneous NLE is straightforward. Sun protection is advisable, and low-potency topical steroids may help

decrease the erythema. Because the cutaneous lesions apparently produce no discomfort in the baby and spontaneously resolve, there is little justification for administering systemic therapies such as corticosteroids or antimalarials. Residual telangiectasia may be treated by a vascular laser.

For cardiac disease, pacemaker implantation and medical management of heart failure is required in many cases. Systemic steroids may be administered to fetuses or babies with heart disease, but their efficacy has not been clearly established by prospective controlled studies (Saleeb *et al*, 1999). In one case of a child with heart failure and progressive cardiomyopathy, despite pacemaker implantation, digoxin, captopril, systemic steroids, and IVIg, plasma exchange were administered (Taylor-Albert *et al*, 1997). The plasma exchange was performed based on the hypothesis that maternal autoantibodies contribute to the disease. The child's condition stabilized, but it is not possible to conclude whether the disease course was affected by the treatments given.

Some investigators have touted the use of systemic steroids as a prophylactic measure administered to the mother during pregnancy (Shinohara *et al*, 1999). In my opinion, however, further data are needed before this approach can be generally recommended. Systemic steroids are not entirely benign, and pregnancy outcomes, discussed below, are usually favorable in any case.

OUTCOMES

Pregnancy NLE is not a common disease, occurring in perhaps 1 of 20,000 live births (Lee and Weston, 1996). Anti-Ro autoantibodies, the antibodies most strongly associated with NLE, are present in about 1 of 200 persons. Thus, even though virtually all women who have a baby with NLE have anti-Ro autoantibodies, very few women who have anti-Ro will have a baby with NLE.

It appears that there are anti-Ro-positive women who have a higher risk of having a baby with NLE. Studies from rheumatology clinics indicate that the risk for anti-Ro-positive women with SLE and related diseases may be in the 5%–15% range (Ramsey-Goldman *et al*, 1986; Lockshin *et al*, 1988). Reports of the risk for women, symptomatic or not, who have already had one baby with NLE having an affected baby in a subsequent pregnancy are 8%–65%, with an overall risk of 25% if data from the five studies cited here are combined (McCune *et al*, 1987; Julkunen *et al*, 1993a; Waltuck and Buyon, 1994; Buyon *et al*, 1998; Neiman *et al*, 2000).

Children The short-term outcomes for children were discussed above. Except for the few cases of children with liver failure, the children who do not have cardiac disease have rather prompt resolution of disease activity and a good short-term outcome. For children with cardiac disease, there is significant mortality and morbidity.

It may be expected that in the long run some children who have NLE will later develop autoimmune disease, based on the fact that there is a family history of autoimmunity (i.e., a mother who has autoantibodies). The question is whether the risk for autoimmune disease is slightly or substantially higher than that of the general population. At this time, there is not enough information to draw a conclusion. It is noteworthy, however, that in a long-term registry follow-up of 49 NLE children and their 45 unaffected siblings, 6 children who had NLE later developed autoimmune diseases or diseases thought possibly to be autoimmune, whereas none of the unaffected siblings developed disease (Martin *et al*, 2002). Specifically, of the 49 children who had NLE, there were 2 with juvenile rheumatoid arthritis, 1 with Hashimoto's thyroiditis, 1 with psoriasis and iritis, 1 with diabetes mellitus and psoriasis, and 1 with congenital hypothyroidism and nephrotic syndrome. In the group of 45 unaffected siblings, there were 2 children with

positive ANA but none with symptoms suggestive of autoimmune disease.

Maternal symptoms Perhaps half of women who have a child with NLE are asymptomatic at the time of presentation of the child. With time, most develop symptoms, which are rarely the same as those of their children. Heart block has not been reported in mothers of babies with NLE, and cutaneous lupus lesions are unusual. In two studies, maternal symptoms were most consistent with Sjögren's syndrome (McCune *et al*, 1987; Julkunen *et al*, 1993b), whereas in other studies diagnoses of systemic lupus erythematosus or undifferentiated connective tissue disease were more frequently seen (Waltuck and Buyon, 1994; Press *et al*, 1996).

AUTOANTIBODIES AND NLE PATHOGENESIS

The autoantibodies originally associated with NLE are anti-Ro, also called anti-SSA (Franco *et al*, 1981). In sera containing anti-Ro, several autoantibody specificities may be present concurrently. These include antibodies to the originally described Ro protein of 60 kDa, antibodies to a nonhomologous protein called 52-kDa Ro, and antibodies to the La (SSB) protein. A comprehensive study examining anti-Ro-related autoantibody specificities in 20 NLE maternal sera using Ouchterlony assays, western blotting, and ELISA found antibodies to 60-kDa Ro in all 20, antibodies to 52-kDa Ro in 18, and antibodies to La in 9 (Lee *et al*, 1994).

Other autoantibody specificities associated with NLE include antibodies to calreticulin (Lieu *et al*, 1989), a 57-kDa protein (Maddison *et al*, 1995), a 75-kDa phosphoprotein (Wang *et al*, 1999), alpha-fodrin (Miyagawa *et al*, 1998), the neonatal heart M1 muscarinic acetylcholine receptor (Borda and Sterin-Borda, 2001), and, in a few cases of cutaneous NLE, U1RNP (Provost *et al*, 1987).

From a diagnostic standpoint, Ouchterlony (immunodiffusion) assays for antibodies to Ro and La remain the most valuable, clinically relevant serologic test.

Autoantibodies and disease It is reasonable to hypothesize that autoantibodies cause NLE. They are invariably present in NLE sera, and they are not random but rather are of a particular set of specificities associated with the Ro family. Disease activity in NLE occurs while maternal autoantibodies are present in the child's circulation and resolves at or before the time that maternal autoantibodies are fully metabolized by the child.

Examination of antibody deposits in human tissue have shown that anti-Ro antibodies are found in both affected and unaffected organs (Lee *et al*, 1987; Lee *et al*, 1989; Reichlin *et al*, 1994). This is perhaps not surprising, given that the Ro and La proteins are normally found in all organs. It does not, however, provide an explanation for why NLE involves heart, skin, and a few other sites but fails to involve many other organs.

In my lab, maternal sera from cutaneous NLE and cardiac NLE cases have been compared in several assays in order to determine whether there are differences in the maternal autoantibodies that correlate with differences in the expression of disease. These studies have been largely negative. Cutaneous NLE and cardiac NLE autoantibodies were not detectably different with regard to IgG antibody subclass (Bennion *et al*, 1990); western blotting patterns using skin extract, heart extract, and extract from other organs; or precipitation of hY RNA associated with 60-kDa Ro (Lee *et al*, 1996). One difference detected was an appreciably higher titer of antibodies to 60-kDa Ro in cardiac NLE sera compared with cutaneous NLE sera, $p < 0.02$ (Lee *et al*, 1994).

In addition to the question of organ specificity in NLE, there is the question of why fetuses or newborns develop disease while their mothers exposed to the same autoantibodies are unaffected

or affected in a different way. It has been reported that there are isoforms of 52-kDa Ro that are expressed differently during different stages of gestation (Buyon *et al*, 1997). Also, RNA associated with 60 kDa Ro are expressed differently at different stages of gestation (Fraire-Velazquez *et al*, 1999). Whether the differential expression leads to disease susceptibility has yet to be determined.

ANIMAL MODELS OF NLE

Reproduction of NLE in an animal model has been attempted by many investigators. Several years ago, my lab injected pregnant guinea pigs with anti-Ro/La-containing human maternal NLE serum (Lee and Coulter, unpublished data 1986). The pups were examined for antibody deposits and development of disease. Human IgG deposits were found in all pups and presented uniformly in all organs (Fig 2). These findings are similar to those in human tissues examined. None of the pups developed disease, although the number of animals tested was rather small by comparison to that in later studies using mice.

In 1992, Alexander and coworkers demonstrated abnormalities of repolarization in isolated rabbit cardiac muscle perfused with anti-Ro-positive serum (Alexander *et al*, 1992). Garcia and colleagues reported heart block in isolated rabbit hearts perfused with anti-Ro-positive serum or with purified anti-52-kDa Ro (Garcia *et al*, 1994; Viana *et al*, 1998). Boutjdir and coworkers reported the reproduction of heart block in isolated rat hearts and also the induction of bradycardia and prolonged PR interval (but not complete heart block) in newborn mice whose mothers received human anti-Ro/La-containing IgG during pregnancy (Boutjdir *et al*, 1998; Mazel *et al*, 1999). Miranda-Carus observed conduction abnormalities in about 10% of mouse pups born to mothers immunized to 60-kDa Ro, 52-kDa Ro, or La (Miranda-Carus *et al*, 1998). In pups whose mothers were immunized to 52-kDa Ro, the conduction abnormality was third-degree block in some cases. Histologic findings in the affected hearts were not reported. Overall, these studies, subject to some limitations, provide strong support for the hypothesis that anti-Ro/La autoantibodies are pathogenic.

A mechanistic link between anti-52-kDa Ro and cardiac disease has been proposed by Eftekhari and colleagues, who identified a cross-reactivity between 52-kDa Ro and the serotonergic 5-HT₄ receptor (Eftekhari and Salle 2000; Eftekhari and Roegel 2001). Purified anti-5-kDa Ro/anti-5-HT₄-receptor antibodies antagonized the serotonin-induced L-type calcium channel

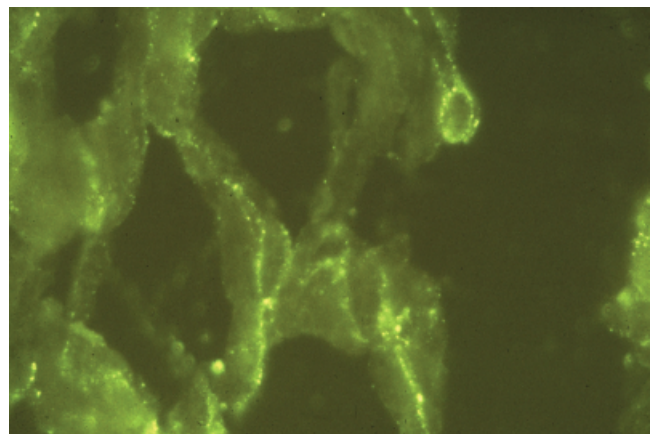


Figure 2. Human IgG deposits detected by direct immunofluorescence in cardiac muscle of a guinea pig pup whose mother was injected during pregnancy with human maternal neonatal lupus serum. Antibody deposits were observed in all organs tested, including organs not known to be affected in neonatal lupus.

activation on human atrial cells. Female mice immunized to produce antibodies to 52-kDa Ro and 5-HT₄-receptor peptides gave birth to pups who had bradycardia, type I or II atrioventricular block, skin rashes, or neuromotor problems. The rashes were not characterized histologically. Inspection of the hearts revealed an abnormally small size, with underdevelopment of the ventricles. The histology of the atrioventricular region was not reported. As in the human disease and the mouse model of Miranda-Carus, only a minority of pups developed heart block. This model provides supporting evidence that NLE autoantibodies cause disease, and it raises the possibility that disease is induced as a result of antibody cross-reactivities. The degree to which this model recapitulates or may be refined to recapitulate human NLE remains to be elucidated.

Tran and coworkers injected pregnant mice with human anti-Ro/La-containing sera (Tran *et al*, 2002). The pups were noted to have human IgG binding to apoptotic cells in the heart, skin, liver, and bone, but not in the thymus, lung, brain, or gut. In studies of cultured human cells, it had been reported that anti-Ro/La-antibody binding to apoptotic cardiac cells increases secretion of TNF- α from cultured macrophages (Miranda-Carus *et al*, 2000) and results in differentiation of cardiac fibroblasts to a scarring phenotype (Clancy *et al*, 2002). In this animal model, however, the apoptotic complexes were not associated with an inflammatory reaction and gross findings of NLE were not observed.

SUMMARY

NLE is a disease strongly associated with maternal autoantibodies to Ro and La. These autoantibodies cross the placenta and are found in the child's circulation. Disease activity resolves by the time the maternal autoantibodies are metabolized. Much circumstantial and experimental evidence implicates autoantibodies in the pathogenesis of NLE, but the full explication of disease pathogenesis has yet to be accomplished.

REFERENCES

Alexander E, Buyon JP, Provost TT, Guarnieri T: Anti-Ro/SS-A antibodies in the pathophysiology of congenital heart block in neonatal lupus syndrome, an experimental model. *In vitro* electrophysiologic and immunocytochemical studies. *Arthritis Rheum* 35:176-189, 1992

Bennion SD, Ferris C, Lieu TS, Reimer CB, Lee LA: IgG subclasses in the serum and skin in subacute cutaneous lupus erythematosus and neonatal lupus erythematosus. *J Invest Dermatol* 95:643-664, 1990

Borda E, Sterin-Borda L: Autoantibodies against neonatal heart M1 muscarinic acetylcholine receptor in children with congenital heart block. *J Autoimmun* 16:143-150, 2001

Boutjdir M, Chen L, Zhang ZH, Tseng CE, El-Sherif N, Buyon JP: Serum and immunoglobulin G from the mother of a child with congenital heart block induce conduction abnormalities and inhibit L-type calcium channels in a rat heart model. *Pediatr Res* 44:11-19, 1998

Buyon JP, Hiebert R, Copel J, *et al*: Autoimmune-associated congenital heart block: demographics, mortality, morbidity and recurrence rates obtained from a national neonatal lupus registry. *J Am Coll Cardiol* 31:1658-1666, 1998

Buyon JP, Tseng CE, Di Donato F, Rashbaum W, Morris A, Chan EK: Cardiac expression of 52beta, an alternative transcript of the congenital heart block-associated 52-kd SS-A/Ro autoantigen, is maximal during fetal development. *Arthritis Rheum* 40:655-660, 1997

Clancy RM, Askanase AD, Kapur RP, *et al*: Transdifferentiation of cardiac fibroblasts, a fetal factor in anti-SSA/Ro-SSB/La antibody-mediated congenital heart block. *J Immunol* 169:2156-2163, 2002

Eftekhari P, Roegel JC, Lezoualc'h F, Fischmeister R, Imbs JL, Hoebeke J: Induction of neonatal lupus in pups of mice immunized with synthetic peptides derived from amino acid sequences of the serotonergic 5-HT₄ receptor. *Eur J Immunol* 31:573-579, 2001

Eftekhari P, Salle L, Lezoualc'h F, *et al*: Anti-SSA/Ro52 autoantibodies blocking the cardiac 5-HT₄ serotonergic receptor could explain neonatal lupus congenital heart block. *Eur J Immunol* 30:2782-2790, 2000

Fraire-Velazquez S, Herrera-Esparza R, Villalobos-Hurtado R, Avalos-Diaz E: Ontogeny of Ro hYRNAs in human heart. *Scand J Rheumatol* 28:100-105, 1999

Franco HL, Weston WL, Peebles C, Forstot SL, Phanuphak P: Autoantibodies directed against sicca syndrome antigens in the neonatal lupus syndrome. *J Am Acad Dermatol* 4:67-72, 1981

Garcia S, Nascimento JHM, Bonfa E, Levy R, Oliveira SF, Tavares AV, Campos de Carvalho AC: Cellular mechanism of the conduction abnormalities induced by serum from anti-Ro/SSA-positive patients in rabbit hearts. *J Clin Invest* 93:718-724, 1994

Julkunen H, Kaaja R, Wallgren E, Teramo K: Isolated congenital heart block: fetal and infant outcome and familial incidence of heart block. *Obstet Gynecol* 82:11-16, 1993a

Julkunen H, Kurki P, Kaaja R, *et al*: Isolated congenital heart block. Long-term outcome of mothers and characterization of the immune response to SS-A/Ro and to SS-B/La. *Arthritis Rheum* 36:1588-1598, 1993b

Kanagasegar S, Cimaz R, Kurien BT, Brucato A, Scofield RH: Neonatal lupus manifests as isolated neutropenia and mildly abnormal liver functions. *J Rheumatol* 29:187-191, 2002

Lee LA: Neonatal lupus erythematosus and congenital heart block. In *Dermatology at the Millennium: The Proceedings of the 19th World Congress of Dermatology*. Dyal-Smith D, Marks R (eds). London: The Parthenon Publishing Group, 1999, p. 273-277

Lee LA, Alvarez K, Gross T, Harley JB: The recognition of human 60-kDa Ro ribonucleoprotein particles by antibodies associated with cutaneous lupus and neonatal lupus. *J Invest Dermatol* 107:225-228, 1996

Lee LA, Coulter S, Emer S, Chu H: Cardiac immunoglobulin deposition in congenital heart block associated with maternal anti-Ro autoantibodies. *Am J Med* 83:793-796, 1987

Lee LA, Frank MB, McCubbin VR, Reichlin M: The autoantibodies of neonatal lupus erythematosus. *J Invest Dermatol* 102:963-966, 1994

Lee LA, Gaither KK, Coulter SN, Norris DA, Harley JB: Pattern of cutaneous immunoglobulin G deposition in subacute cutaneous lupus erythematosus is reproduced by infusing purified anti-Ro (SSA) autoantibodies into human skin-grafted mice. *J Clin Invest* 83:1556-1562, 1989

Lee LA, Sokol RJ, Buyon JP: Hepatobiliary disease in neonatal lupus: prevalence and clinical characteristics in cases enrolled in a national registry. *Pediatrics* 109:E11, 2002

Lee LA, Weston WL: Special considerations concerning the cutaneous manifestations of rheumatic diseases in children. In *Cutaneous manifestations of rheumatic diseases*. Sontheimer RD, Provost TT (eds). Baltimore: Williams & Wilkins, 1996, p. 323-344

Lieu TS, Newkirk MM, Arnett FC, Lee LA, Deng JS, Capra JD, Sontheimer RD: A major autoepitope is present on the amino terminus of a human SS-A/Ro polypeptide. *J Autoimmunity* 2:367-374, 1989

Lockshin MD, Bonfa E, Elkon K, Druzyn ML: Neonatal lupus risk to newborns of mothers with systemic lupus erythematosus. *Arthritis & Rheumatism* 31:697-701, 1988

Maddison PJ, Lee L, Reichlin M, Sinclair A, Wasson C, Schemmer G, Reichlin M: Anti-p57: a novel association with neonatal lupus. *Clin Exp Immunol* 99:42-48, 1995

Martin V, Lee LA, Katholi M, Buyon JP: Long-term followup of children with neonatal lupus and their unaffected siblings. *Arthritis Rheum* 46:2377-2383, 2002

Mazel JA, El-Sherif N, Buyon J, Boutjdir M: Electrocardiographic abnormalities in a murine model injected with IgG from mothers of children with congenital heart block. *Circulation* 99:1914-1918, 1999

McCuistion CH, Schoch EP Jr: Possible discoid lupus erythematosus in newborn infant: Report of a case with subsequent development of acute systemic lupus erythematosus in mother. *Arch Dermatol* 70:782-785, 1954

McCune AB, Weston WL, Lee LA: Maternal and fetal outcome in neonatal lupus erythematosus. *Ann Intern Med* 106:518-523, 1987

Miranda-Carus ME, Askanase AD, Clancy RM, *et al*: Anti-SSA/Ro and anti-SSB/La autoantibodies bind the surface of apoptotic fetal cardiocytes and promote secretion of TNF-alpha by macrophages. *J Immunol* 165:5345-5351, 2000

Miranda-Carus ME, Boutjdir M, Tseng CE, DiDonato F, Chan EK, Buyon JP: Induction of antibodies reactive with SSA/Ro-SSA/La and development of congenital heart block in a murine model. *J Immunol* 161:5886-5892, 1998

Miyagawa S, Yanagi K, Yoshioka A, Kidoguchi K, Shirai T, Hayashi Y: Neonatal lupus erythematosus: maternal IgG antibodies bind to a recombinant NH2-terminal fusion protein encoded by human alpha-fodrin cDNA. *J Invest Dermatol* 111:1189-1192, 1998

Neiman AR, Lee LA, Weston WL, Buyon JP: Cutaneous manifestations of neonatal lupus without heart block: Characteristics of mothers and children enrolled in a national registry. *J Pediatr* 137:674-680, 2000

Press J, Uziel Y, Laxer RM, Luy L, Hamilton RM, Silverman ED: Long-term outcome of mothers of children with complete congenital heart block. *Am J Med* 100:328-332, 1996

Provost TT, Watson R, Gammon WR, Radowsky M, Harley JB, Reichlin M: The neonatal lupus syndrome associated with UIRNP (nRNP) antibodies. *New England J Med* 316:1135-1138, 1987

Ramsey-Goldman R, Hom D, Deng J-S, *et al*: Anti-SS-A antibodies and fetal outcome in maternal systemic lupus erythematosus. *Arthr Rheum* 29:1269-1273, 1986

Reichlin M, Brucato A, Frank MB, Maddison PJ, McCubbin VR, Wolfson-Reichlin M, Lee LA: Concentration of autoantibodies to native 60 kd Ro/SS-A and de-

- natured 52 kD Ro/SS-A in eluates from the heart of a child who died with congenital complete heart block. *Arthr Rheum* 37:1698-1703, 1994
- Saleeb S, Copel J, Friedman D, Buyon JP: Comparison of treatment with fluorinated glucocorticoids to the natural history of autoantibody-associated congenital heart block: retrospective review of the research registry of neonatal lupus. *Arthr Rheum* 42:2335-2345, 1999
- Schoenlebe J, Buyon JP, Zitelli BJ, Friedman D, Greco MA, Knisely AS: Neonatal hemochromatosis associated with maternal autoantibodies against Ro/SS-A and La/SS-B ribonucleoproteins. *Am J Dis Child* 147:1072-1075, 1993
- Selander B, Cedergren S, Domanski H: A case of severe neonatal lupus erythematosus without cardiac or cutaneous involvement. *Acta Paediatr* 87:105-107, 1998
- Shinohara K, Miyagawa S, Fujita T, Aono T, Kidoguchi K: Neonatal lupus erythematosus: results of maternal corticosteroid therapy. *Obstet Gynecol* 93:952-957, 1999
- Taylor-Albert E, Reichlin M, Toews WH, Overholt ED, Lee LA: Delayed dilated cardiomyopathy as a manifestation of neonatal lupus: case reports, autoantibody analysis, and management. *Pediatrics* 99:733-735, 1997
- Tran HB, Macardle PJ, Hiscock J, Cavill D, Bradley J, Buyon JP, Gordon TP: Anti-La/SSB antibodies transported across the placenta bind apoptotic cells in fetal organs targeted in neonatal lupus. *Arthr Rheum* 46:1572-1579, 2002
- Viana VS, Garcia S, Nascimento JH, et al: Induction of *in vitro* heart block is not restricted to affinity purified anti-52 kDa Ro/SSA antibody from mothers of children with neonatal lupus. *Lupus* 7:141-147, 1998
- Waltuck J, Buyon JP: Autoantibody-associated congenital heart block: outcome in mothers and children. *Ann Intern Med* 120:544-551, 1994
- Wang D, Buyon JP, Zhu W, Chan EK: Defining a novel 75-kDa phosphoprotein associated with SS-A/Ro and identification of distinct human autoantibodies. *J Clin Invest* 104:1265-1275, 1999
- Watson R, Kang JE, May M, Hudak M, Kickler T, Provost TT: Thrombocytopenia in the neonatal lupus syndrome. *Arch Dermatol* 124:560-563, 1988
- Weston WL, Morelli JG, Lee LA: The clinical spectrum of anti-Ro-positive cutaneous neonatal lupus erythematosus. *J Am Acad Dermatol* 40:675-681, 1999